



SAMPLE PATIENT REPORT

Lower Arterial

Name: Glaysher Medical Technologies, Adam Glaysher
Date of Birth: **Age:**

Patient ID: 800-526-5611
Gender:

Ref By: Parks Medical Electronics
Examined By:
Read By: Parks Flo-Lab

Date: 10/16/2014 12:21 PM
Accession/Case:
Room:

Segmental BP

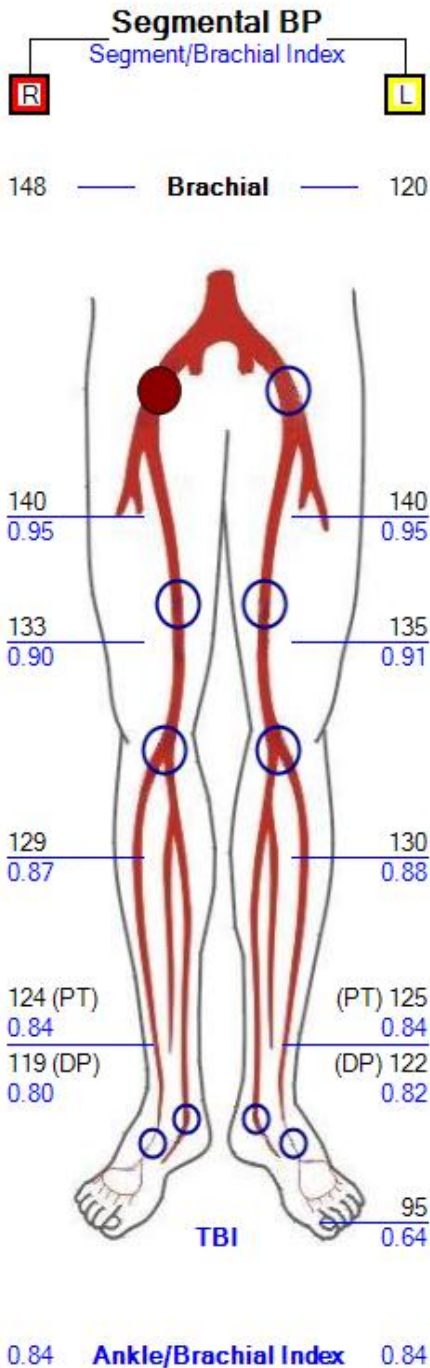
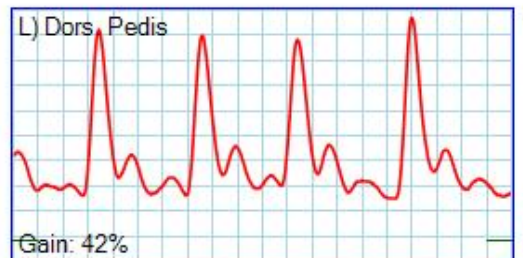
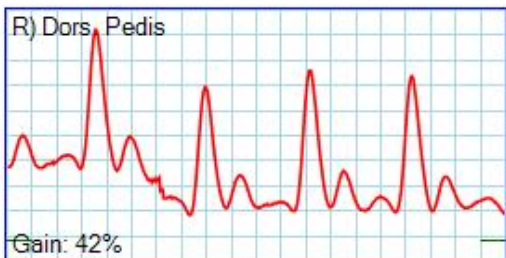
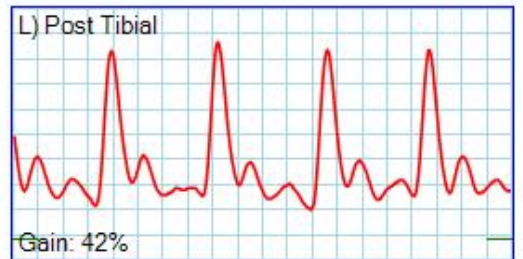
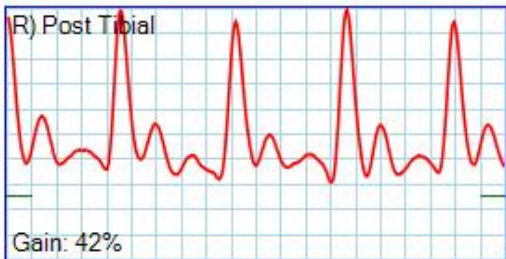
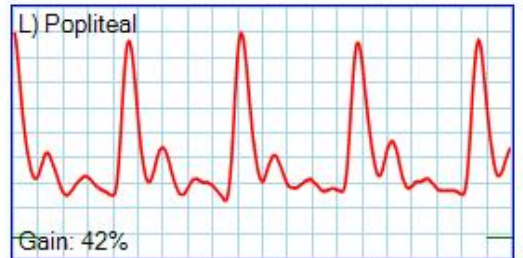
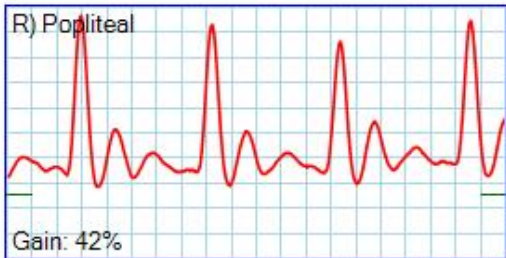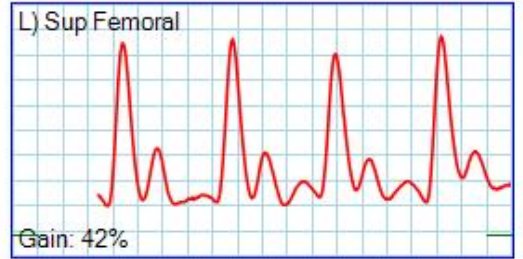
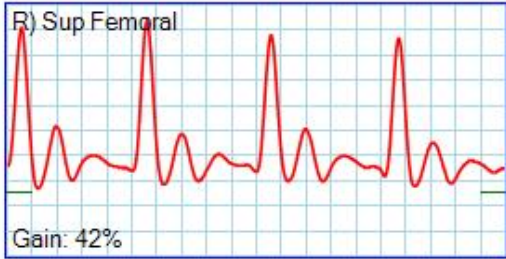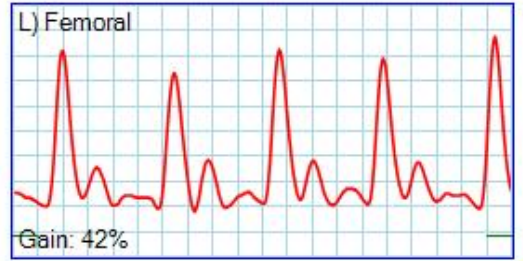
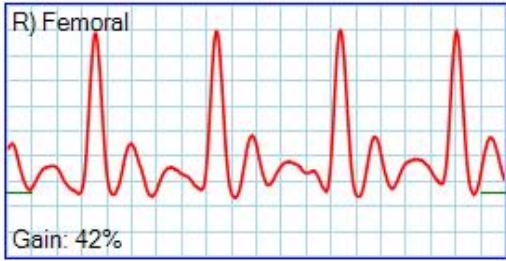
Right

Brachial:	148	Index
High Thigh:	140	0.95
Low Thigh:	133	0.90
Calf:	129	0.87
Ankle (PT):	124	0.84
Ankle (DP):	119	0.80
Digit:		

Left

Brachial:	120	Index
High Thigh:	140	0.95
Low Thigh:	135	0.91
Calf:	130	0.88
Ankle (PT):	125	0.84
Ankle (DP):	122	0.82
Digit:	95	0.64

Doppler



VPR

